

# Machine Learning Approaches in Developing Expert System for Medical Image Analysis with respect to THR: From Detection to Diagnosis

Dr. Sandhya Tatekalva<sup>1</sup>

<sup>1</sup>Department of Computer Science, S.V.University, Tirupati, A.P., INDIA.

Email ID: [dr.sandhyasatish@gmail.com](mailto:dr.sandhyasatish@gmail.com)

\*Corresponding Author: [dr.sandhyasatish@gmail.com](mailto:dr.sandhyasatish@gmail.com)

Available online at: <http://www.ijcert.org>

Received: 02/01/2022,

Revised:13/01/2022,

Accepted:19/01/2022,

Published: 24/01/2022

**Abstract:** - Machine learning approaches are increasingly successful in image-based diagnosis, disease prognosis, and risk assessment. There is a need to find any deviation that can be acquired in position of artificial femur after the log time of surgery, well in advance thereby overcome the adverse socio economic and psychological burden to both the patient as well as the surgeon. The aim of the study is to develop a non-invasive, ultrasound-based, method of diagnosing acetabular cup loosening at an early stage before any major bone erosion has taken place. The proposed study will build on a previously successful technique for the diagnosis of loosening of the femoral stem component of a THR. This paper highlights the steps like box filter section, mainly first order and second order, followed by key points selection, key points extraction, key point matching and finally finding the deviation through motion vector analysis. The data for this research has been collected from different hospitals in Andhra Pradesh and Tamil Nadu.

**Keywords:** Machine learning, Developing Expert System, THR, Medical Image Analysis, First order and Second order Box filters.

## 1. Introduction

A detailed review of the literature provides a better understanding of the different development stages and trends that have characterised the history of total hip replacement, leading to the reasoning of the current state of the art fixation methods, component types, materials selection, failure factors and diagnostic techniques. Existing literature, along with the annual reports of national joints registries, were utilised to follow these different development stages; placing them in a historical context.

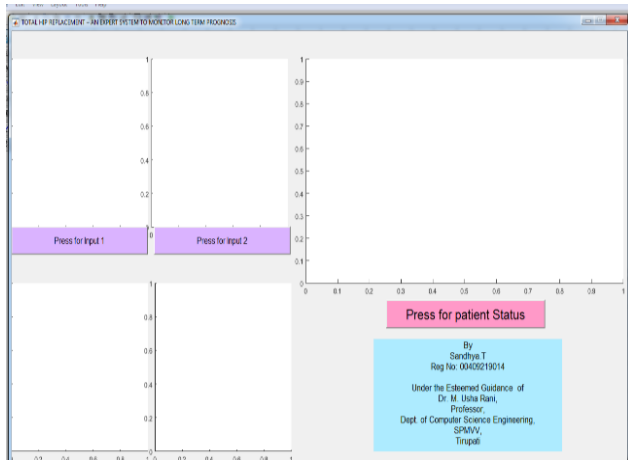
Image processing has been proposed as an

alternative, more sensitive method for THR loosening diagnosis. Despite the fact that acetabular cups have a higher revision rate over femoral components, most of the existing literature is stem related. Also, the limited acetabular cup studies only examined late loosening scenarios.

Results are achieved in two ways i.e GUI and in common method using MATLAB software. The proposed algorithm has been tested with different image databases. Basically the algorithm developed was confined with four threshold levels of patient conditions like no deviation, very small deviation, small deviation and high deviation of the hip bones.

**Test 1: Step by Step Procedure in GUI:**

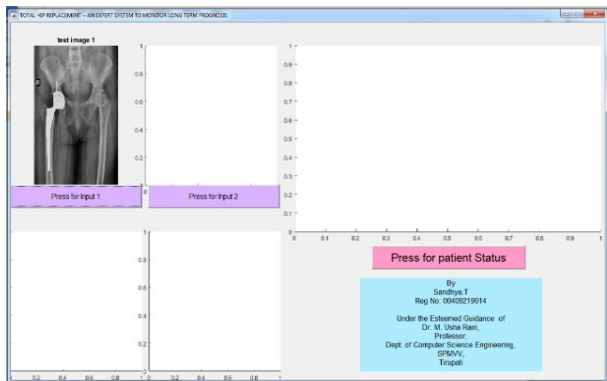
**Step 1:** Run the GUI Implementation Program in MATLAB R2016; then a window is opened as shown in below



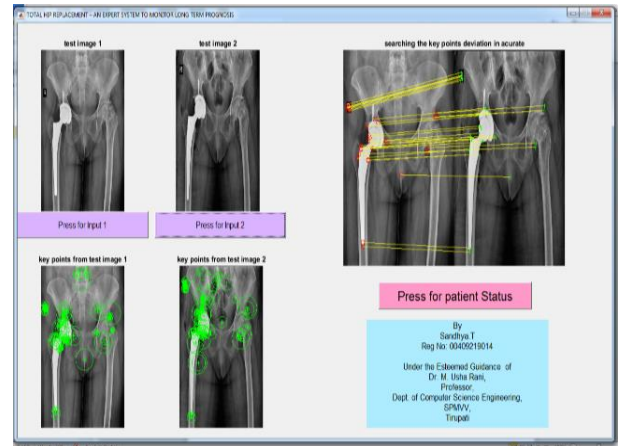
**Fig. 1: GUI Implementation screen**

**Step 2:** In left upper corner we can observe ‘press for input 1’ here by clicking on this popup button, one window of current Directory is opened, Here we can select the reference image 1 (i.e., patient X-ray just of the surgery) as shown in Fig. 2.

**Step 3:** Same as the above step by clicking on ‘press for input 2’ popup button we can select reference image 2 (i.e., patient X-ray post time of the surgery) as shown in Fig. 3. For creating a flexible environment to the patients, by selecting the second reference image reaming all out puts appear in the GUI Window.

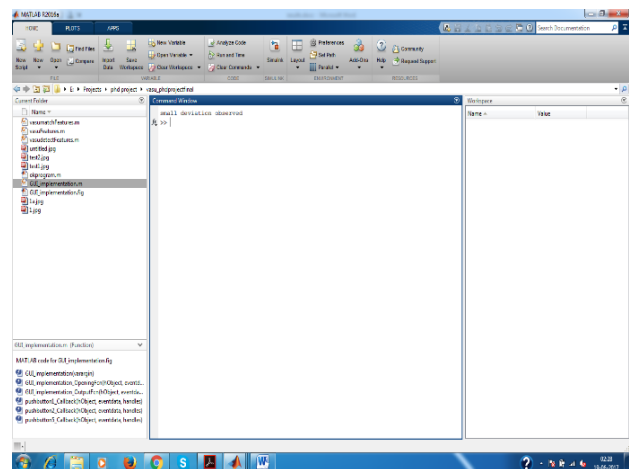


**Fig. 2: Selection of Reference image 1**



**Fig. 3: Selection of Reference image 2 and final out put images**

**Step 4:** Click on “Press for Patient Status” for knowing the status of the patient (i.e. the automation system will display the condition of the artificial rod inserted in hip) in command window as shown in bellow figure e.g. displayed like “small deviation as observed”.

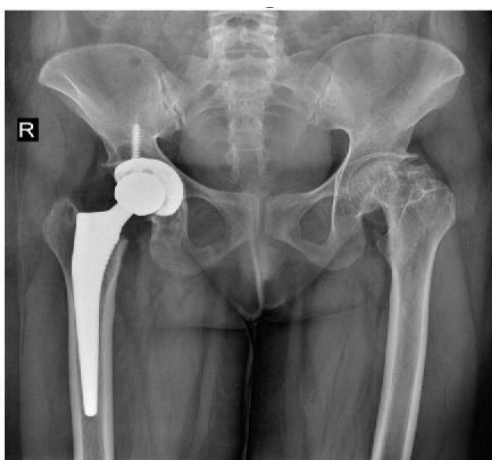
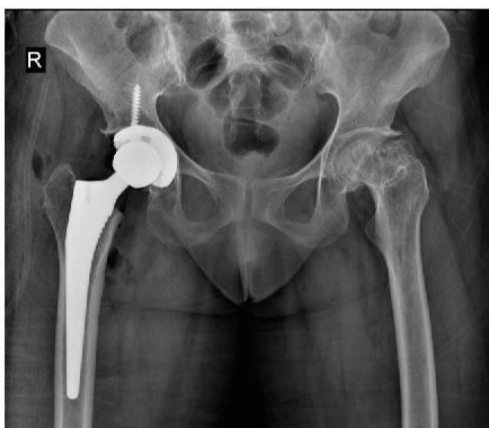
**Fig. 4: Status of the patient**

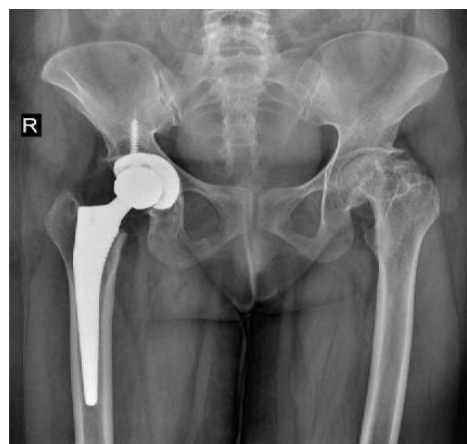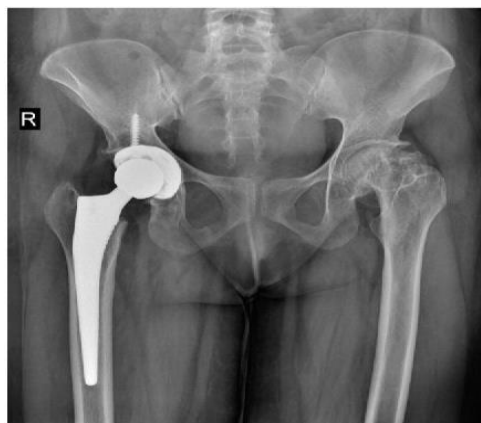**Procedure to run the matlab Program**

Run the main Program and select two reference images of the patient and we can observe the status of the patient in command window. GUI analysis is used for end users (like patients and Doctors) whereas this method of analysis is useful for technical people and researchers because of more information in the form of key points, spectrum of reference images, information related to

Motion vectors etc. Some of the pictorial representations are discussed below. The analysis is done by comparing patients, one has some small deviation and another has no deviation in artificial Femur (artificial rod).

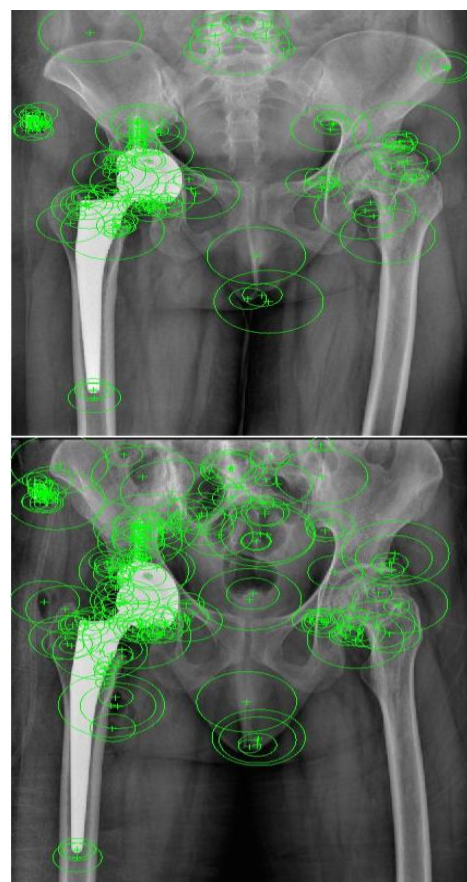


**Fig. 5: Patient 1 reference images**



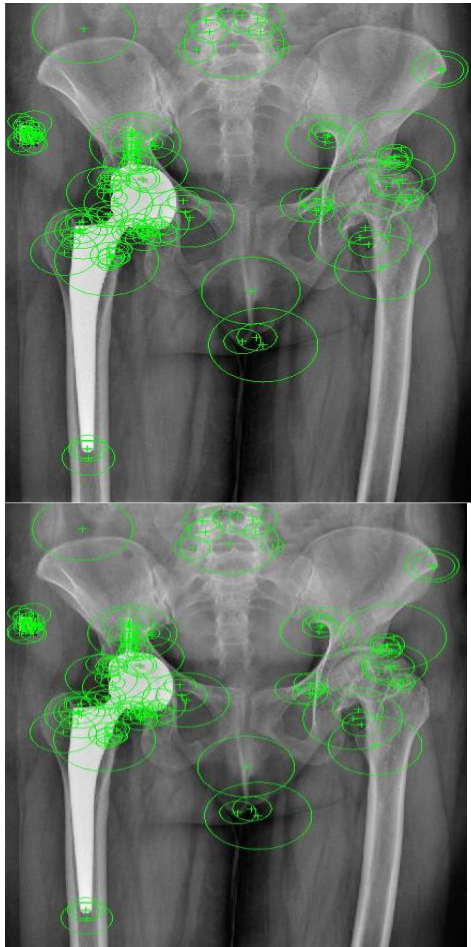
**Fig. 6: Patient 2 reference images**

Consider two patients say patient 1 and patient 2 and their reference images as shown above. These images considered are per operative and postoperative respectively.



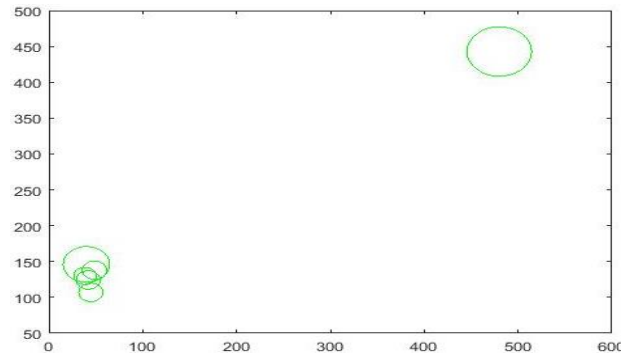
**Fig. 7: Key Points selection of Patient 1**

Green circles in the above images are the key points from the patient 1. These key points are automatically selected using the algorithms.



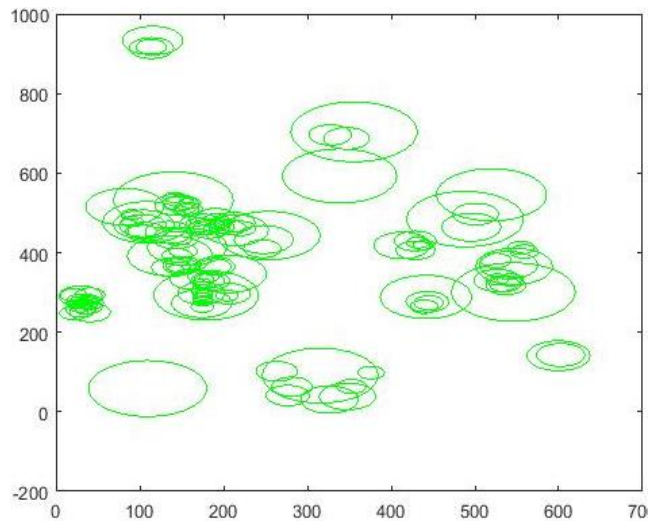
**Fig. 8: Key Points selection of Patient 2**

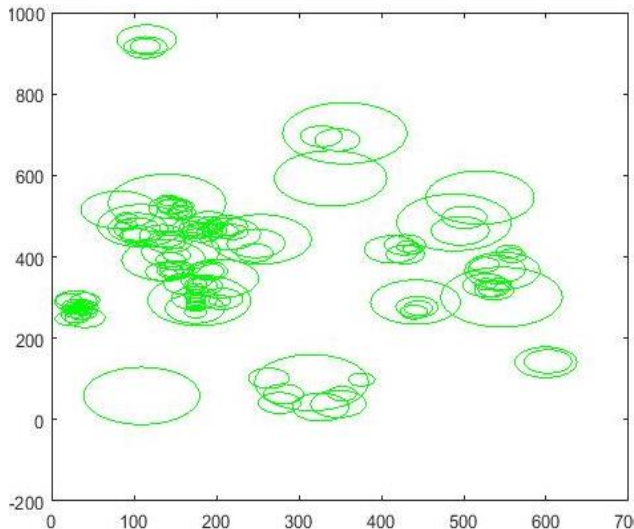
Similarly, for patient 2 also we calculated the key points. In this study, we implemented the algorithm for almost 200 to 300 key points from each reference image. It can be modified or adjust the key point depending upon our requirement. For example, if complex images are going to be used, then we can increase the number of key points. Also, the algorithm is designed in such a way that it adaptively selecting the key points.



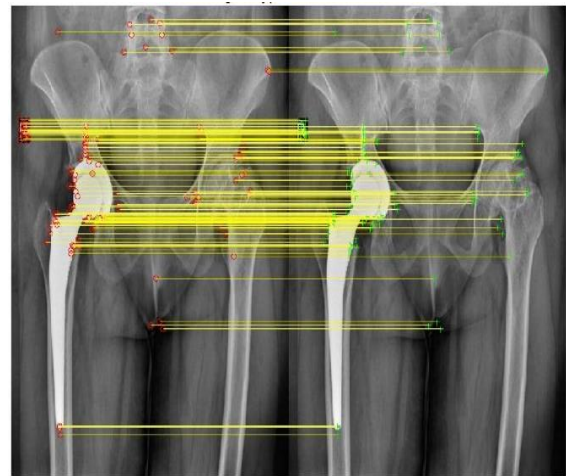
**Fig. 9: Key Points selection of Patient 1 graphical view**

The above images are the same key points as in Fig 7 but the location is predicted by using graphical method. In this, 2-d view of images locates the key points in special domain. Similarly for patient 2 key points are calculated in Fig. 10.

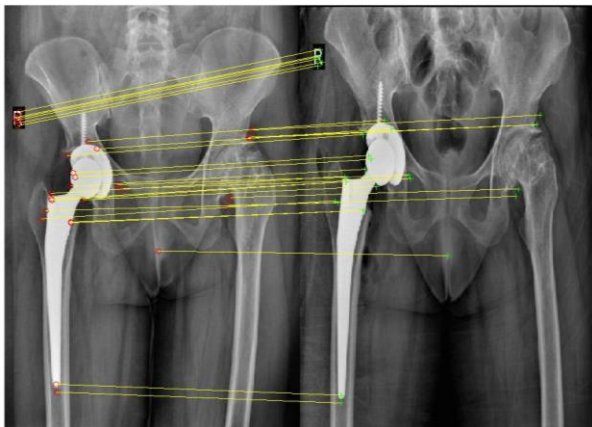




**Fig. 10:** Key Points selection of Patient 2 graphical view



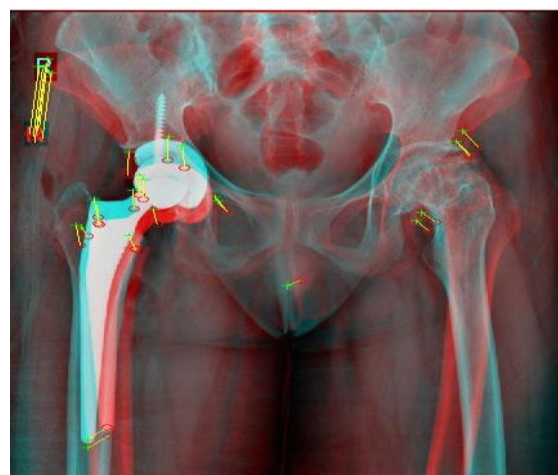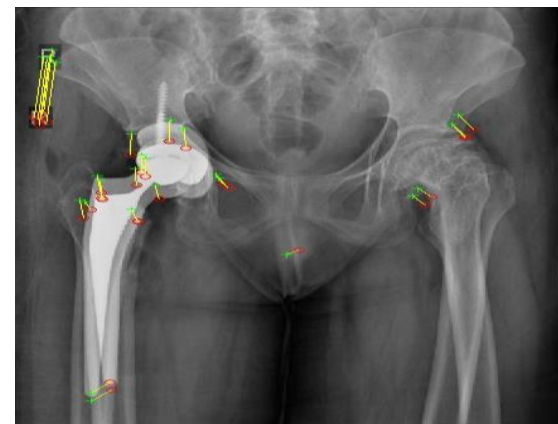
**Fig. 10b:** Matching the key Points of both the reference images of patient 2



**Fig. 10a:** Matching the key Points of both the reference images of patient 1

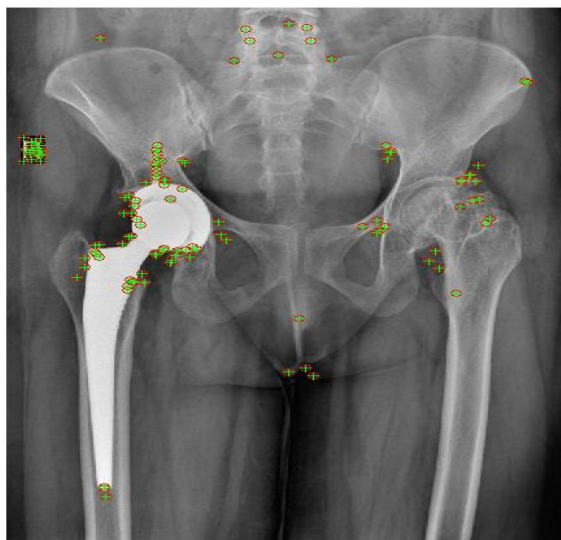
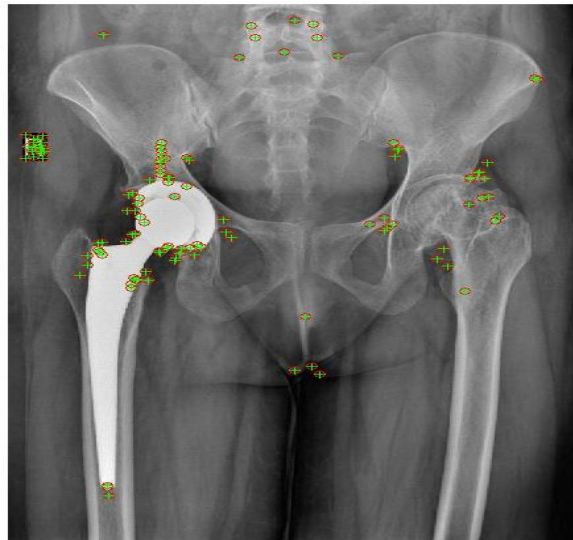
After locating the key points the next procedure is matching the key points from one to another reference images. Here it can be noticed that the slope of the yellow lines are indicating the deviation of artificial femur. This slope is directly proportional to the deviation of artificial femur i.e. if slope is more the deviation is also more.

Let us compare Fig. 10a and Fig. 10b, it can be observed that slope of the yellow lines whereas in Fig. 10 b, lines are parallel which means that no deviation is identified. The same results can be expected with Motion vector calculation.



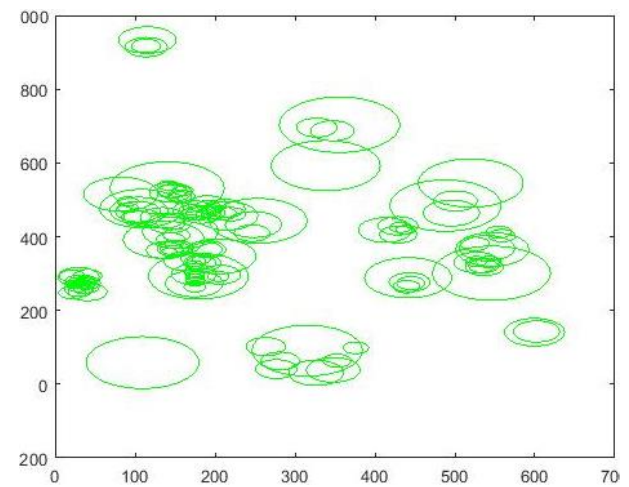
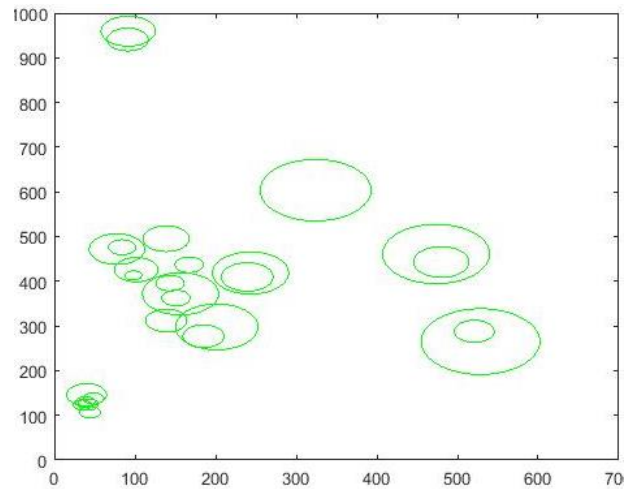
**Fig. 11:** Motion vector analysis of Patient 1

The above images are two different ways of finding the motion vectors. In Motion vector analysis of Patient 1, the left image, yellow lines are observed and in right side image, there is slight variation in color. This will tell us small deviation in artificial femur.



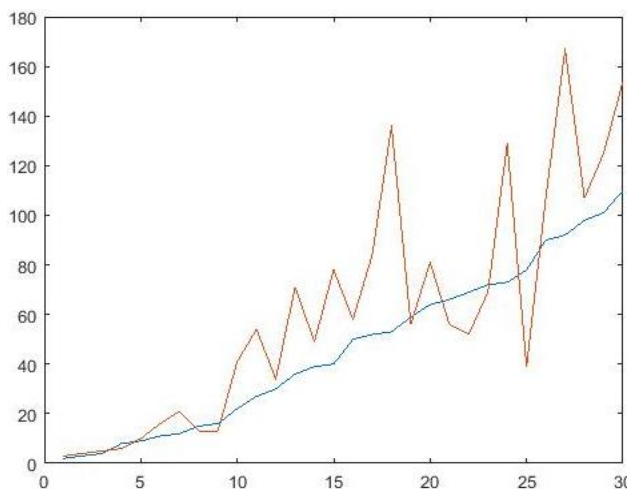
**Fig. 12: Motion vector analysis of Patient 2**

The motion vector analysis of patient 2, the yellow lines do not appear in the left image and no color change is seen in the right image. This indicates no deviation in artificial femur.

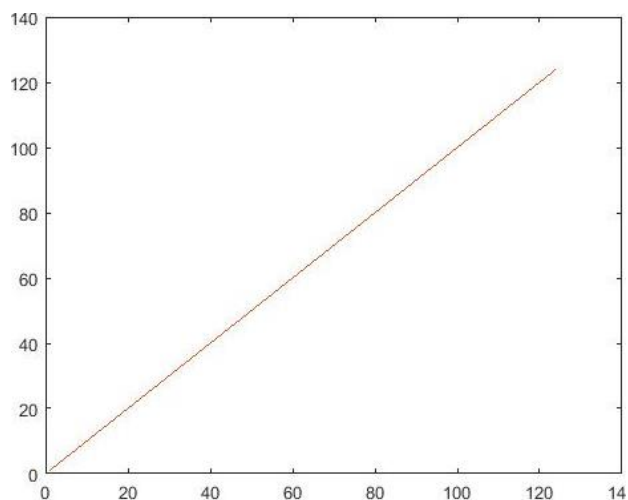


**Fig. 13: Identification of key matched points Patient 1 and patient 2**

The above diagram is identification of matched key points in Fig. 11 and Fig. 12 as special domain. Combination of two circles indicates matching of key points.

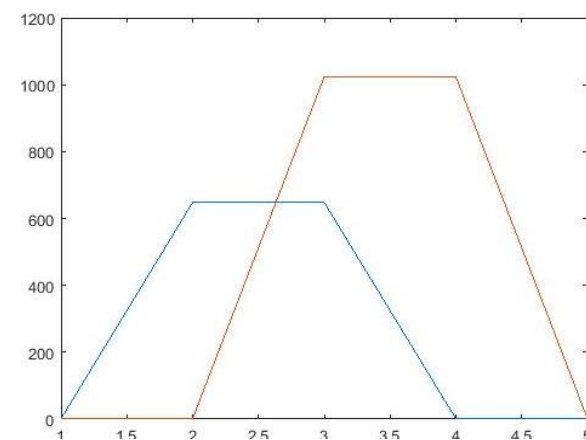
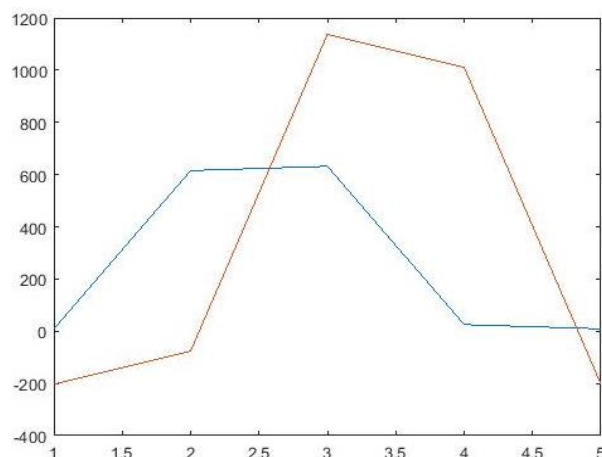


**Fig. 14: Non linearity in Patient 1**

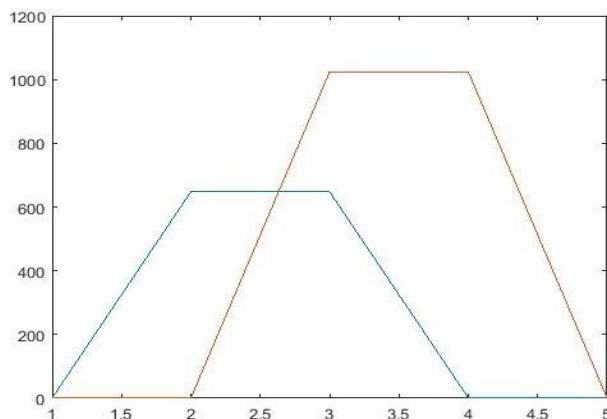


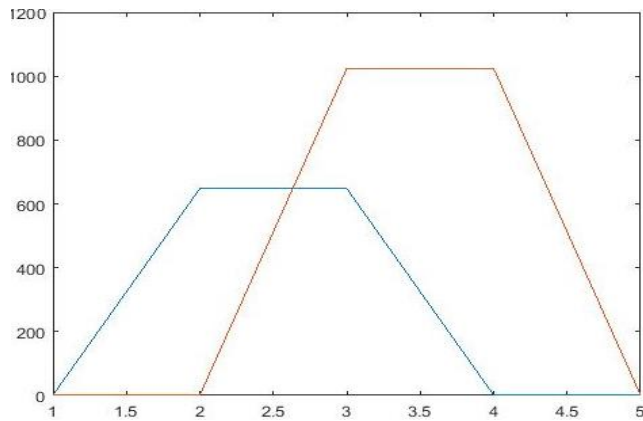
**Fig. 15: Linearity in Patient 2**

In the above Fig. 14 brown and blue colors are not merged and represent nonlinear pattern in patient 1. And in Fig. 15 these two colors are merged, which is linear indicating no deviation in artificial femur of patient 2 and nonlinear indicating small deviation in patient 1.



**Fig. 16: Uncertainty in Patient 1**

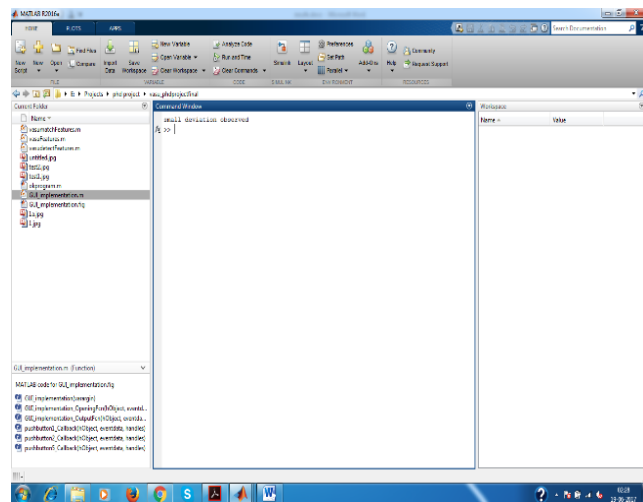




**Fig. 17: Certainty in Patient 2**

The above images Fig. 16 and Fig. 17 are similar to linearity images but here depending up on slops deviation is calculated.

The major strength of the algorithm is that it can identify the deviation in multiple views like motion vectors, special coordinates, linearity measures etc. After performing all processes, finally it displays results in command Window as shown below.



**Fig. 18: Display the final results in command window**

## 2. Conclusion:

In this paper “Machine Learning Approaches in Developing Expert System for Medical Image Analysis with respect to THR : From Detection to Diagnosis”, it has been clearly explained that how to develop a non-invasive,

ultrasound-based, method of diagnosing acetabular cup loosening at an early stage before any major bone erosion has taken place. The research work highlights the steps like box filter section, mainly first order and second order, followed by key points selection, key points extraction, key point matching and finally finding the deviation through motion vector analysis. In this it has been examined that the use of algorithms to monitor long term progress, providing a flexible environment to doctors as well as patients. The entire process is based on automation – by giving two reference images of a patient to the software that shows the status of artificial femur, whether aligned properly or not. The reference images are tested with multiple algorithms. The main feature of this expert system is that the key points are automatically identified (proposed method) which means that there is less probability of mistake, than if a human selects the key points (existing method). Another feature is that this system gives reliable outputs when compared with the existing methods.

## 2.1. Future work:

- Selection of undesired features while locating the key points is the complexity observed in this methodology, although minimized in the present study.
- In future, the unwanted key points from the reference images can be avoided or removed by using adaptive filters.
- Again there could be a limitation that enhancing reference images could result in unwanted reference points being enhanced. These complexities may be overcome by using segmentation algorithms and choosing the region of interest.

## References:

- [1] Marques, O. (2011). Practical image and video processing using MATLAB. Hoboken: Wiley-IEEE Press.
- [2] Sandhya, Tatekalva., Prof.Usha Rani, M., & Dr.Maruthi Krishna, M. (2017). Image Processing Techniques for Measuring the Acetabular Cup Orientation from Anteversion Angle of Revised Cemented Total Hip Arthroplasty (THA). International journal of Emerging Technology in Computer Science & Electronics (IJETCSE), ISSN: 0976-1353, volume 24, issue 1.
- [3] David G. Lowe. (2004). Distinctive Image Features from Scale-Invariant Key points. Computer Science Department University of

- British Columbia, Vancouver, B.C., Canada.
- [4] Marius, Muja., Radu. BogdanRusuy., Gary Bradskiy., & David Lowe. (2011). REIN - A Fast, Robust, Scalable Recognition Infrastructure. University of British Columbia, Canada. IEEE Xplore, published in IEEE International conference on Robotics and Automation (ICRA). DOI: 10.1109/ICRA.2011.5980153. e-ISBN: 978-1-61284-385-8.
- [5] T. Sandhya., & Prof. M. Usha Rani. (2016). CONTEMPORARY REVISION ANALYSIS OF THE HIP REPLACEMENT REGISTRIES IN INDIA. *International Journal of Computational Science, Mathematics and Engineering*. Volume-3-Issue-11-November-2016 ISSN-2349-8439
- [6] T. Sandhya., & Prof. M. Usha Rani. (2019). Need for Computerized Automated Machine (CAM) for finding THR issues in Patients. *International Journal of Innovative Technology and Exploring Engineering (IJITEE)*. ISSN: 2278-3075, Volume-8, Issue-7C2.
- [7] S.J. Ferguson., J.T. Bryant., R. Ganz., & K. Ito. (2003). An in vitro investigation of the acetabularlabral seal in hip joint mechanics. *Journal of Biomechanics*. volume 36, issue 2, pages 171-178.
- [8] Joachim Pfeil., & W.E.Siebert. (2010). *Minimally Invasive Surgery in Total Hip Arthroplasty*. Heidelberg: Springer. Doi: <https://doi.org/10.1007/978-3-642-00897-9>.
- [9] Chen-Kun Liawa., Rong-SenYangb., Sheng-MouHoub., Tai-Yin Wuc., & Chiou-Shann. (2006). A Simple Mathematical Standardized Measurement of Acetabulum Anteversion after Total Hip Arthroplasty. ISSN 1748-670X print/ISSN 1748-6718 online.
- [10] G. Wu, S. Siegler., P. Allard., C. Kirtley., A. Leardini., D. Rosenbaum., M. Whittle., D. D. D'Lima., L. Cristofolini., H. Witte., O. Schmid., I. Stokes. (2002). ISB Recommendation on Definitions of Joint Coordinate System of Various Joints for the Reporting of Human Joint Motion-part I: Ankle, Hip, and Spine. *Journal of Biomechanics*, 2002, 35(4): 543-48.
- [11] C. Nikou., B. Jaramaz., A. M. DiGioia., & T. J. Levison. (2000). Description of Anatomic Coordinate System and Rationale for use in an Image-guided Total Hip Replacement System. *Medical Image Computing and Computer-Assisted Intervention-MICCAI*. Lecture Notes of Computer Science. Vol. 1935, pp. 1188-1194.
- [12] Rafael C, Gonzalez., & Richard E. Woods. (2008). *Digital Image Processing*. published by Pearson Edition, Inc. Publishing as Prentice Hall, copyright © 2008. ISBN: 978-81-317-2695-2.
- [13] Don, Fussell. (2010). *Image Processing*. University of Texas at Austin CS384G - Computer Graphics Fall.
- [14] Elaine Rich., & Kelvin Knight. (2009). *Artificial Intelligence*. TMH.
- [15] Fayyad U., Piatetsky-Shapiro G., & Smyth, P. (1996). *From Data Mining to Knowledge Discovery in Databases*. AI Magazine, American Association for Artificial Intelligence.

### Bibliography:



Dr. Sandhya Tatekalva,  
MCA, Ph.D., Academic Consultant,  
S.V.University, Tirupati, Andhra  
Pradesh, India. Email:  
[dr.sandhyasatish@gmail.com](mailto:dr.sandhyasatish@gmail.com)